

THE
Oxford[®]
Partial Knee

SURGICAL TECHNIQUE

BIOMET[®]
ORTHOPEDICS

This brochure is presented to demonstrate the surgical technique of Prof. D.W. Murray, Mr. J. Goodfellow, Prof. J. O'Connor, and Mr. C. Dodd, of the Nuffield Orthopaedic Centre, Oxford, U.K. Biomet, as the manufacturer of this device, does not practice medicine and does not recommend this or any other surgical technique for use on a specific patient. The surgeon who performs any procedure is responsible for determining and utilizing the appropriate techniques for such procedure for each individual patient.

CONTENTS

The Oxford® Partial Knee	2
Femoral Components	2
Tibial Components	2
Meniscal Bearings	2
Patient Selection	3–4
The Learning Curve	4
Preoperative Planning	5
Preoperative X-ray Template	6
Open vs. Minimally Invasive Technique	7
The Operation	8–28
Positioning the Limb	8
Incision	8
Step 1: Osteophyte Excision	9
Step 2: Tibial Plateau Resection	10–13
Step 3: The Femoral Drill Holes and Alignment	14–16
Step 4: Femoral Saw Cut	17
Step 5: First Milling of the Condyle	19–20
Step 6: Equalizing the Flexion and Extension Gaps	20–21
Step 7: Confirming Equality of the Flexion and Extension Gaps	22
Step 8: Preventing Impingement	23
Step 9: Final Preparation of the Tibial Plateau	24–25
Step 10: Final Trial Reduction	26
Step 11: Cementing the Components	27–28
Instrument Key	29–31
Appendix	32–34
Package Insert	35–37

THE OXFORD® PARTIAL KNEE

The Oxford® Partial Knee is the natural evolution of the original meniscal arthroplasty, which was first used in 1976.¹ It continues to offer the advantage of a large area of contact throughout the entire range of movement for minimal polyethylene wear, as seen in the Oxford® Knee Phase I & II.^{2,3}

Since 1982, the Oxford® Partial Knee has been successfully used to treat anteromedial osteoarthritis.⁴ If performed early in this disease process, the operation can slow the progress of arthritis in the other compartments of the joint and provide long-term relief of symptoms.⁵

The Oxford® implant is based on its clinically successful predecessors which achieved 98 percent survival at 10 years^{5,6} with an average wear rate of 0.03mm per year.^{2,3}

FEMORAL COMPONENTS

The unique, spherically designed femoral components are made of cast cobalt chromium molybdenum alloy for strength, wear resistance and biocompatibility. The design is available in five sizes to provide an optimal fit. The sizes are parametric and have the following radii of curvature.

The articulating surface of the femoral component is spherical and polished to a very high tolerance. The appropriate size of femoral component is chosen preoperatively by overlaying templates on a lateral radiograph of the knee.

X-Small	=	20.3mm
Small	=	22.0mm
Medium	=	23.8mm
Large	=	25.6mm
X-Large	=	27.5mm

TIBIAL COMPONENTS

The tibial components, also made of cast cobalt chromium molybdenum alloy, are available in seven sizes, both right and left. Their shapes are based on those of the successful AGC® Total Knee System.⁷ They provide greater tibial bone coverage and avoid component overhang anteriomedially.

MENISCAL BEARINGS

The bearings are Direct Compression Molded ultra high molecular weight polyethylene (UHMWPE), manufactured from ArCom® Direct Compression Molded polyethylene for increased wear resistance.¹²

There are five bearing sizes to match the radii of curvature of the five femoral component sizes. For each size, there is a range of seven thicknesses, from 3mm to 9mm.

PATIENT SELECTION

There are well-defined circumstances in which the Oxford® medial arthroplasty is appropriate and certain criteria must be fulfilled for success.

- The operation is most suitable for the treatment of anteromedial osteoarthritis.⁴
- Both cruciate ligaments must be intact. The posterior cruciate is seldom diseased in osteoarthritic knees, but the anterior cruciate is often damaged and is sometimes absent. Since the implant is completely unconstrained in the anteroposterior plane, the stability of the prosthesis depends on an intact cruciate. Stability cannot be restored if the anterior cruciate ligament is badly damaged or absent. This deficiency is a contraindication to the procedure.
- Medial or lateral subluxation (visible preoperatively on the anteroposterior radiograph) or posterior tibial bone loss (on the lateral radiograph) strongly suggest damage to the cruciate mechanism; therefore, the procedure is contraindicated.⁸
- In medial unicompartmental replacement, the lateral compartment should be well preserved, with an intact meniscus and full thickness of articular cartilage. This is best demonstrated by the presence of a full thickness 'joint space' visible on an AP radiograph taken with the joint stressed into valgus.⁹ However, a grade I cartilage defect, marginal osteophytes and even localized areas of erosion of the cartilage on the medial margin of the lateral condyle are frequently seen at surgery and are not contraindications to medial compartment arthroplasty.
- Malalignment of the limb must be passively correctable to neutral and not beyond. A good way to confirm this is to take stressed radiographs.⁹
- The degree of deformity is not as important as its ability to be passively corrected by the application of a valgus force. Varus deformity of more than 15 degrees can seldom be passively corrected to neutral; therefore, this figure represents the outer limit. Soft tissue release should never be performed. If the medial collateral ligament has shortened and passive correction of the varus is impossible, the arthritic process has progressed beyond the stage suitable for this procedure, and thus the procedure is contraindicated.
- Flexion deformity should be less than 15 degrees. Unicompartmental arthroplasty has a limited ability to improve flexion deformity. If the preoperative deformity is excessive, it should not be employed.
- The knee must be able to flex to at least 110 degrees under anesthetic to allow access for preparation of the femoral condyle.

- Patellofemoral arthritis is not a contraindication. Extensive fibrillation and full thickness erosions are commonly seen on the patellar facet and patellar groove of the femur, but realignment of the limb by unicompartmental replacement unloads these damaged areas of the patellofemoral joint. No correlation has been found between the success of the operation and the state of the patellofemoral joint. In more than 500 cases reported by Murray, et al.⁵ and Price, et al.,⁶ no knee was revised because of patellofemoral problems.
- Several other contraindications to unicompartmental replacement which have been proposed have been found unnecessary. Neither the patient's age, weight nor activity level are contraindications, nor is the presence of chondrocalcinosis.
- Unicompartmental arthroplasty is contraindicated in all forms of inflammatory arthritis. (The pathological changes of early rheumatoid arthritis can be confused with those of medial compartment osteoarthritis.) The high success rates reported^{5,6} were achieved in patients with anteromedial osteoarthritis, and they may not be achieved with other diagnoses. The Oxford® implant has also been used successfully in the treatment of primary avascular necrosis, but the numbers are too few to be statistically significant.
- Lateral unicompartmental osteoarthritis is more difficult to treat by unicompartmental replacement and the Oxford® meniscal bearing knee is contraindicated for use in the lateral compartment.
- The Oxford® knee is not designed for use in the lateral compartment. The ligaments of the lateral compartment are more elastic than those of the medial, and a 10 percent rate of early dislocation of the bearing is reported. Access through a small incision is more difficult laterally than medially. Gunther, et al. recommends the Vanguard M™ series fixed bearing unicompartmental replacement for lateral compartment arthroplasty using the Oxford® Knee Phase II.¹⁴
- The final decision whether or not to perform unicompartmental arthroplasty is made when the knee has been opened and directly inspected.

THE LEARNING CURVE

This surgical technique should be used in association with the instructional video of the operation. As with other surgical procedures, errors of technique are more likely when the method is being learned. **To reduce these to a minimum, surgeons are required by the FDA in the United States and strongly recommended throughout the world, to attend an Instructional Course on the Oxford® knee before attempting the operation.**

PREOPERATIVE PLANNING

The trays containing the tibial instruments and tibial trial components (Figure 1) are used with all sizes of femurs.




Figure 1

The five sizes of femoral components have different radii of curvature, and there is a separate tray of femoral instruments for each femoral size (Figure 2). The trays are color-coded and each contains instruments and trial components specific for one size of femoral component.



Femoral Size X-Small

Femoral Size Small

Femoral Size Medium

Femoral Size Large

Figure 2

Femoral Size X-Large

PREOPERATIVE X-RAY TEMPLATE

The size of femoral component should be chosen preoperatively using the X-ray template (Figure 3). A true lateral radiograph is required.

Apply the outlines on the template to the X-ray image of the medial femoral condyle. The line along the central peg of the implant should be parallel with the long axis of the femoral shaft. The outer surface of the diagrammatic component should lie about 2mm outside the radiographic image to allow for the thickness of articular cartilage. The posterior facet of the prosthesis should extend to, but not beyond, the superior margin of the posterior articular facet of the femur (Figure 4).

A medium size femoral component is appropriate for most patients. In fact, it was the only size used in the Phase I and II implants.

However, it is better to employ the small size in small women and the large size in large men. The extra large is only needed in very big men. If there is doubt between small/medium or medium/large, it is usually best to use the medium.




Figure 3

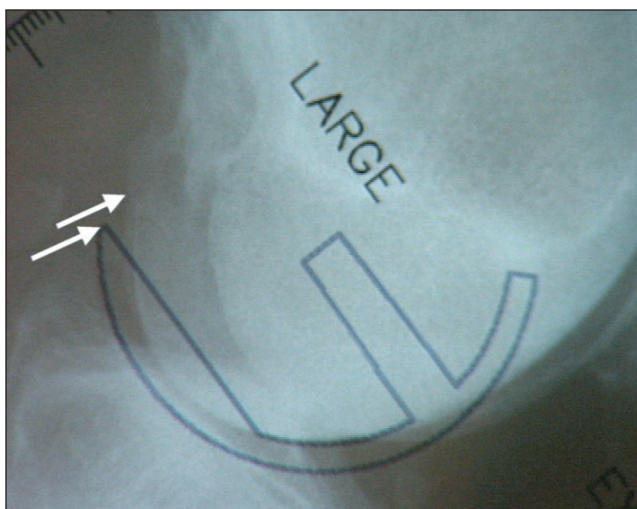


Figure 4

OPEN VS. MINIMALLY INVASIVE TECHNIQUE

One advantage of unicompartmental arthroplasty is that it can be performed through a small incision without dislocating the patella, thus avoiding damage to the synovial reflections of the suprapatellar pouch. This can reduce postoperative pain and allow a more complete and rapid recovery of flexion. With proper use of the Oxford® instruments, the operation can be performed through a small incision with great precision. However, surgeons learning the procedure can extend the soft tissue incision beyond the limits described here with very little increase in postoperative morbidity as long as the integrity of the suprapatellar pouch is preserved.

The open approach, with dislocation of the patella, is no longer recommended. The Oxford® knee system instruments are designed for use through a small incision, and intraoperative dislocation of the patella distorts the ligaments, possibly making the operation more difficult.

THE OXFORD® PARTIAL KNEE SURGICAL TECHNIQUE

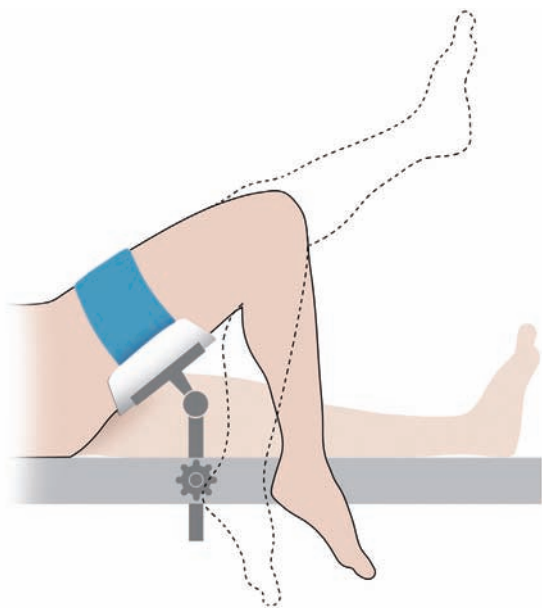


Figure 5

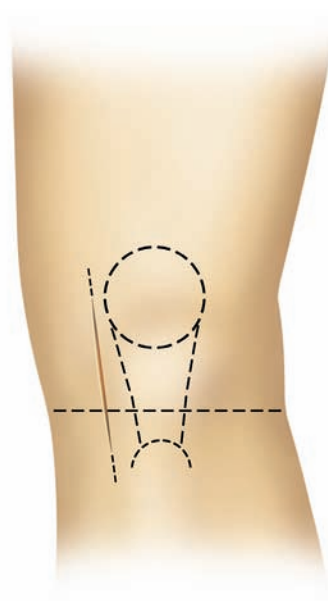


Figure 6

THE OPERATION

POSITIONING THE LIMB

Inflate a thigh tourniquet and place the draped leg on a thigh support, with the hip flexed and the leg dependent. The knee must be free to flex to at least 110 degrees (Figure 5).

INCISION

With the knee flexed to 90 degrees, make a medial parapatellar skin incision from the medial margin of the patella to a point 3cm distal to the joint line (Figure 6). Deepen the incision through the joint capsule. At its upper end, extend the capsular incision obliquely medially for 1 to 2cm into the vastus medialis.

Excise part of the retropatellar fat pad and insert retractors into the synovial cavity. The anterior cruciate ligament can now be inspected to ascertain that it is intact. (Absence of a functioning ACL is a contraindication. If this is found, the operation should be abandoned in favor of a total knee replacement).

Remove medial patellar osteophytes to improve access and, if necessary, excise a thin strip of bone from the medial margin of the patella.

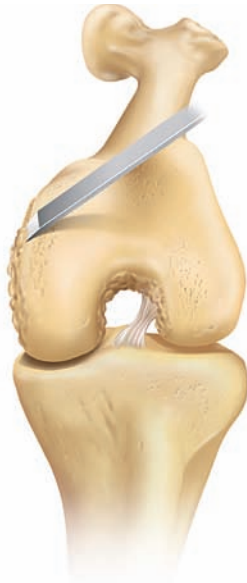

Figure 7

STEP I: OSTEOPHYTE EXCISION

All osteophytes must be removed from the medial margin of the medial femoral condyle and from both margins of the intercondylar notch (Figure 7). The assistant extends and flexes the knee, moving the incision up and down, allowing the various osteophytes to come into view.

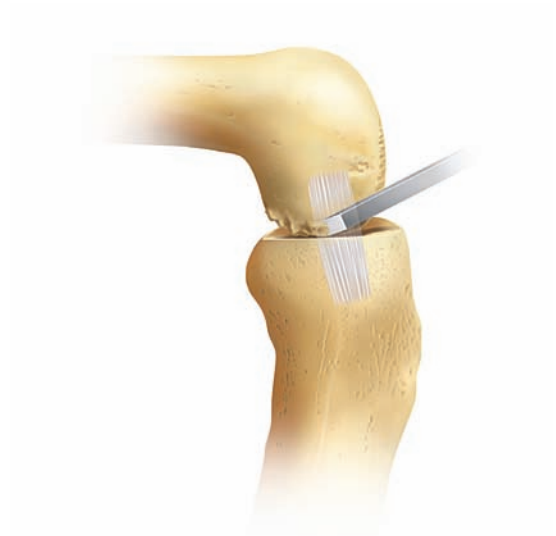

Figure 8

With a narrow chisel (6mm), remove the osteophytes from beneath the medial collateral ligament (Figure 8) and from the posterolateral margin of the medial condyle. This creates room to insert the saw blade into the intercondylar notch during the next step.

THE OXFORD® PARTIAL KNEE SURGICAL TECHNIQUE

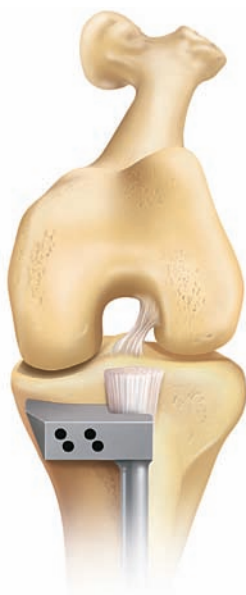

Figure 9

STEP 2: TIBIAL PLATEAU RESECTION

Expose the front of the tibia in the lower part of the wound from the tibial tubercle to the rim of the plateau. Excise as much of the medial meniscus as possible. Do not 'release' any of the fibers of the medial collateral ligament.

Apply the *tibial saw guide (#1)** with its shaft parallel with the long axis of the tibia in both planes (Figures 9 & 10). This will make the horizontal tibial saw cut slope backward and downward seven degrees. Manipulate the upper end of the guide so that its face lies against the exposed bone. A recess accommodates the skin and the patellar tendon laterally (Figure 9).

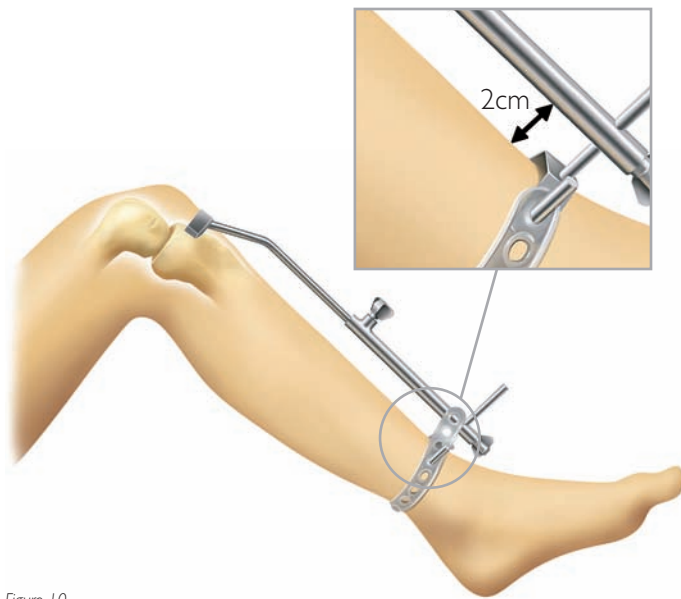


Figure 10

Estimate the level of resection, which varies with the depth of the tibial erosion. The saw cut should pass 2 or 3mm below the deepest part of the erosion (Figure 12). It is better to be conservative with the first cut, as the tibia can be easily re-cut if too little bone has been removed. Having decided the level, fix the guide to the bone with nails passed through the lower set of holes in its head. One *nail* should have a *head* (#3), while the other should be *headless* (#2) (Figures 11 & 12).

* For all instrumentation identified in italics, please refer to "Instrument Key" on pages 29–31.

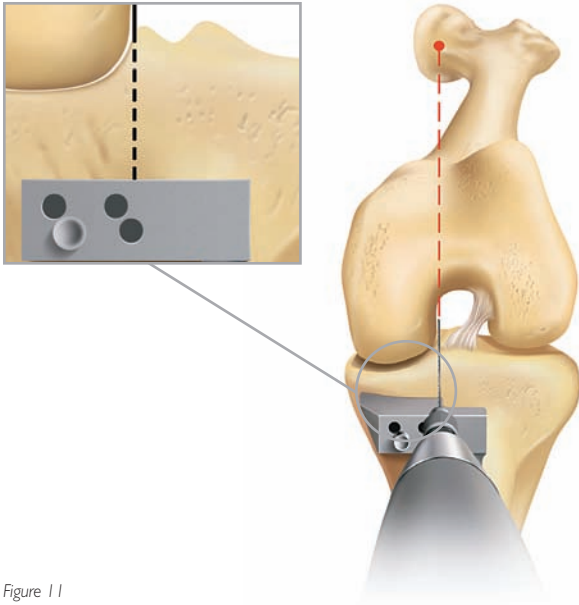


Figure 11

An optional stylus references off intact posterior cartilage. The stylus must be placed on the retained cartilage and not the meniscus. This is best done under direct vision with the joint slightly distracted with a lamina spreader.

Use a reciprocating saw with a stiff narrow blade to make the vertical tibial saw cut. Push the blade into the intercondylar notch close to the lateral margin of the medial femoral condyle, from which the osteophytes were removed in step 1. The saw cut should be just medial to the origin of the ACL avoiding damage to its fibers.

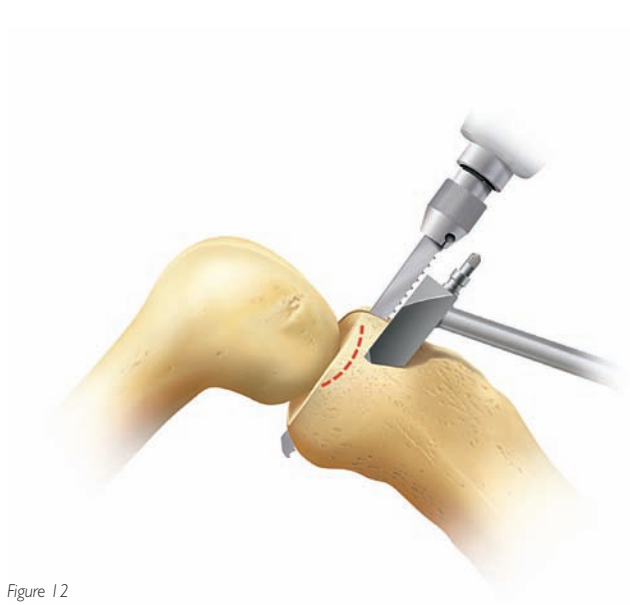


Figure 12

Point the blade toward the head of the femur (Figure 11), the position of which is demonstrated by the assistant who palpates half-way between the pubic tubercle and the anterior superior iliac spine.

The saw must reach to the back of the tibial plateau and a little beyond. Advance the saw vertically down until it rests on the upper surface of the head of the saw guide (Figure 12).

THE OXFORD® PARTIAL KNEE SURGICAL TECHNIQUE

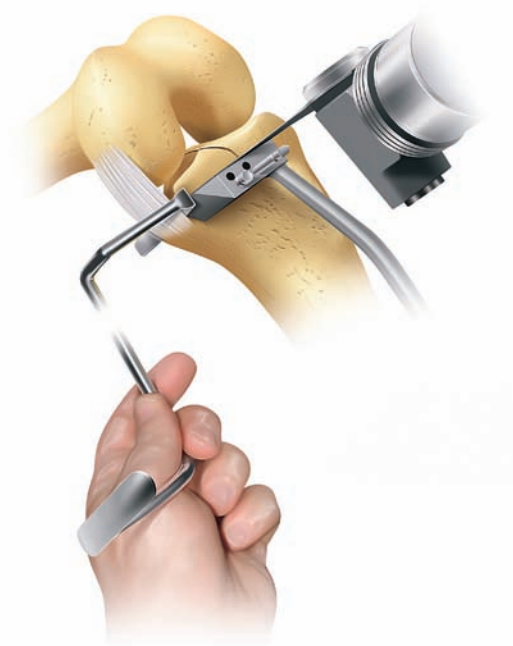

Figure 13

STEP 2 (CONTINUED)

Before making the horizontal cut, insert a retractor to protect the medial collateral ligament.

Use a 12mm wide oscillating saw blade to excise the plateau (Figure 13). Ensure that the blade reaches the back of the joint. When the plateau is loose, lever it up with a broad osteotome and remove (Figure 14). Soft tissue attachments posteriorly may need to be cut with a knife. The posterior horn of the medial meniscus can now be removed.

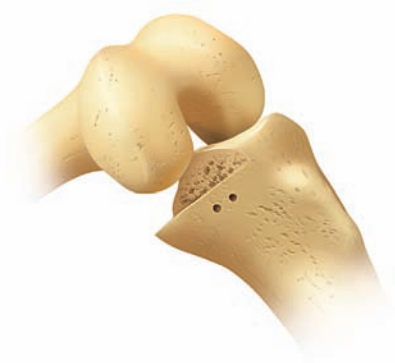

Figure 14

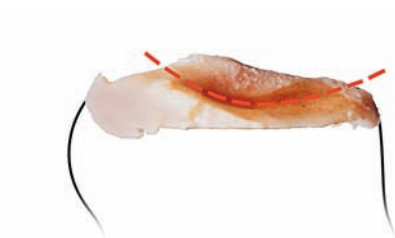

Figure 15

The excised plateau will show the classical lesion of anteromedial osteoarthritis, erosion of cartilage and bone in its mid and anterior parts and preserved cartilage posteriorly (Figure 15). Osteophytes around the edge of the plateau remain attached after its removal.

Use the excised plateau with the tibial templates to choose the size of the tibial implant. Lay templates of the opposite side on the cut surface of the excised plateau to choose the best fit.

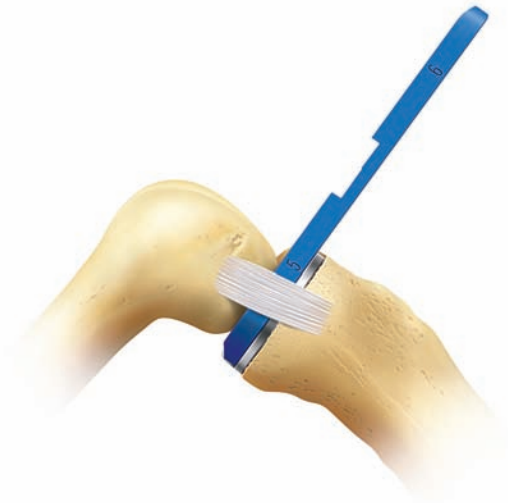

Figure 16

The thickness of bone removed from the tibia must be enough to accommodate the tibial template (#24) and a bearing at least 4mm thick. To check that sufficient bone has been excised, insert the tibial template and a 4mm feeler gauge (#19) (Figure 16). (**Note:** Whenever a feeler gauge is used to measure a gap, the retractors are removed. If they are left in, they have the effect of tightening the soft tissues, which artificially diminishes the gap.)

If the 4mm gauge cannot be inserted or feels tight, more bone must be excised from the tibia. To do this, remove the headed nail and the tibial resector. Replace

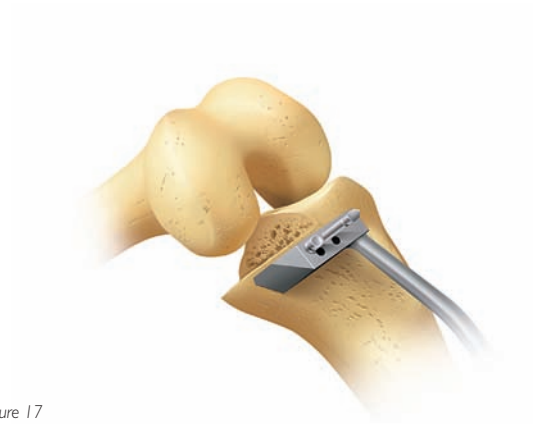

Figure 17

the tibial guide with the headless nail, passing through one of the upper holes. Then replace the headed nail (adjacent to it) in its original bone hole. This displaces the saw guide 3mm distally (Figure 17). Remove another layer of bone and recheck the gap with the tibial template in place to ensure that the 4mm feeler gauge can now be easily inserted (see Figure 16).

THE OXFORD® PARTIAL KNEE SURGICAL TECHNIQUE

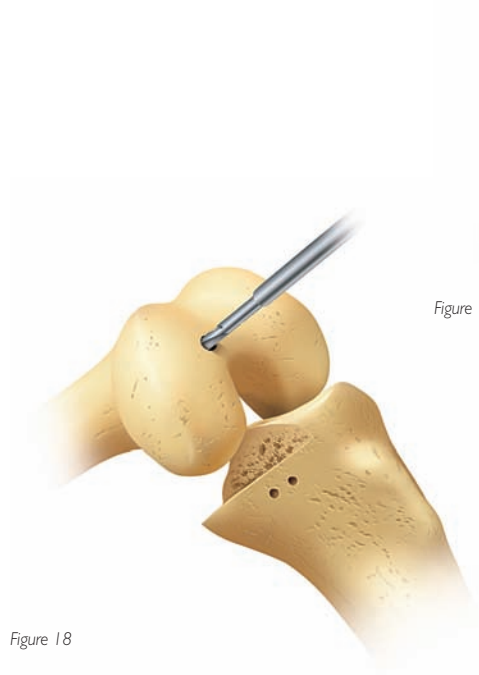


Figure 18

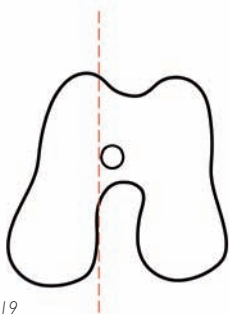


Figure 19

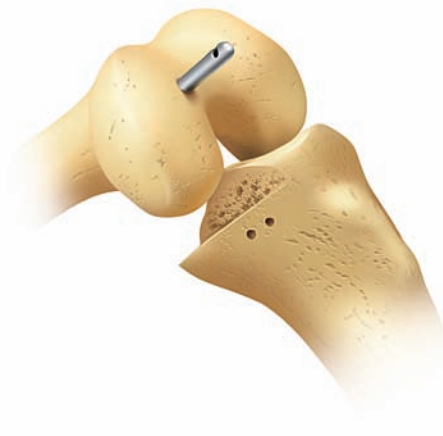

Figure 20

STEP 3: THE FEMORAL DRILL HOLES AND ALIGNMENT

With the knee in about 45 degrees flexion, make a hole in the intramedullary canal of the femur with the 5mm awl (#27) (Figure 18).

The hole must be situated 1cm anterior to the anteromedial corner of the intercondylar notch (Figure 19).

Insert the I/M rod (#5 or 6) until its shoulder is stopped against the bone (Figure 20).

Flex the knee to 90 degrees. This must be done with care, as the medial border of the patella abuts against the rod.

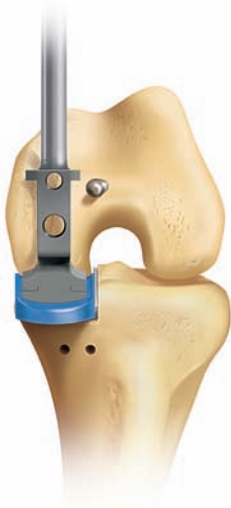

Figure 21

Replace the tibial template, insert the *femoral drill guide* (#15) and place a 3mm feeler gauge between them (Figure 21). If the 3mm gauge is too loose, insert a thicker gauge.

Manipulate the femoral drill guide until it rests in the middle of the condyle when viewed from the front and its handle is aligned parallel with the long axis of the tibia (Figure 21).

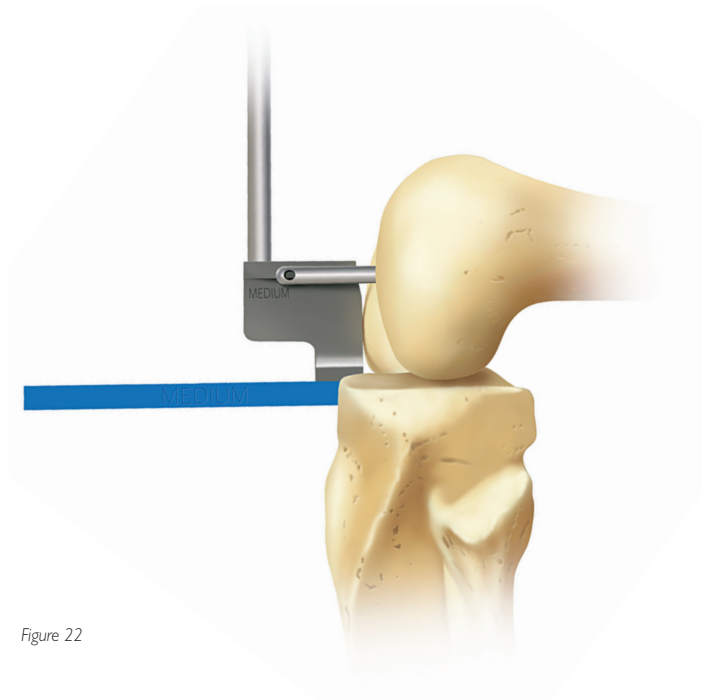


Figure 22

The anterior face must touch the femoral condyle (Figure 22).

By adjusting the degree of flexion of the knee, the upper surface of the drill guide is made to lie parallel with the I/M rod when viewed from the side (Figure 22).

THE OXFORD® PARTIAL KNEE SURGICAL TECHNIQUE

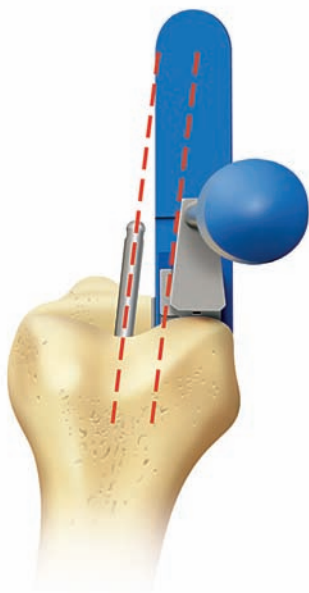


Figure 23

STEP 3 (CONTINUED)

By internally and externally rotating the tibia, make the lateral surface of the seven degree fin lie parallel with the I/M rod when viewed from above (Figure 23).

After fulfilling these five requirements, pass the 4mm drill (#10) through the upper hole in the guide. Drill into the bone up to its stop and leave in place. Confirm all alignments. Then advance the 6mm drill (#11) through the other guide hole until it stops (Figure 24).

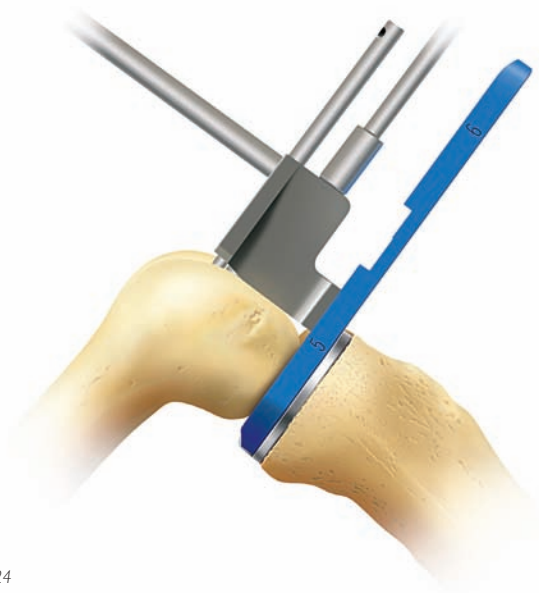


Figure 24

Remove both drills and all instruments from the joint. Use the rod removal hook (#8) to remove the I/M rod.

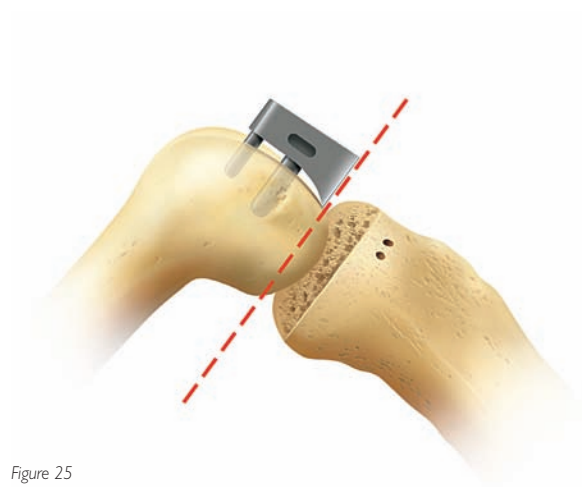


Figure 25

STEP 4: FEMORAL SAW CUT

Insert the *femoral saw block* (#13) into the drilled holes and tap home (Figure 25).

Using the 12mm broad sagittal saw, excise the posterior facet of the femoral condyle, guiding the blade against the underside of the saw block (Figure 26). If the captured femoral saw block is used, guide the blade through the slot in the cutting guide. Take care to avoid damage to the medial collateral and anterior cruciate ligaments.

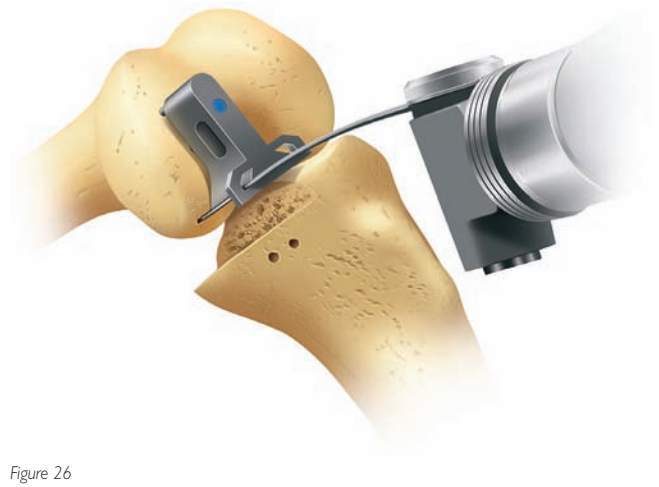


Figure 26

Remove the saw block with the *slap hammer extractor* (#30), taking care not to distort the drill holes.

There is now good access to the back of the joint, and any remnants of the medial meniscus should be completely removed.

THE OXFORD® PARTIAL KNEE SURGICAL TECHNIQUE

Before advancing to the following surgical steps, consult the special note below.

SPECIAL NOTE

The numbers marked on the feeler gauges and the meniscal bearings represent their least thicknesses in millimeters.

The scale of numbers of the spigots is in 1 mm increments, in inverse ratio to the thickness of their flanges.

The spigots must be used as described below:

- **First Milling**

The 0 spigot is designed to automatically remove sufficient bone to allow the femoral component to seat. This amount varies with the degree of arthritic erosion of the condyle.

- **Second Milling**

Spigots 1 to 7 allow bone to be removed in measured quantities (in mm) from the level of the first mill cut. Thus, the number 3 spigot removes 3mm, the number 4, 4mm, etc.

- **Subsequent Milling**

If the last spigot used was a number 3, a number 4 spigot will remove an additional 1 mm of bone (i.e. a total of 4mm since the first milling). However, if the last spigot used was a number 4, a number 5 spigot is required to remove 1 mm of bone (i.e. a total thickness of 5mm since the first milling).

Remember: The spigot number represents the total thickness of bone it removes from the level of the first mill cut.

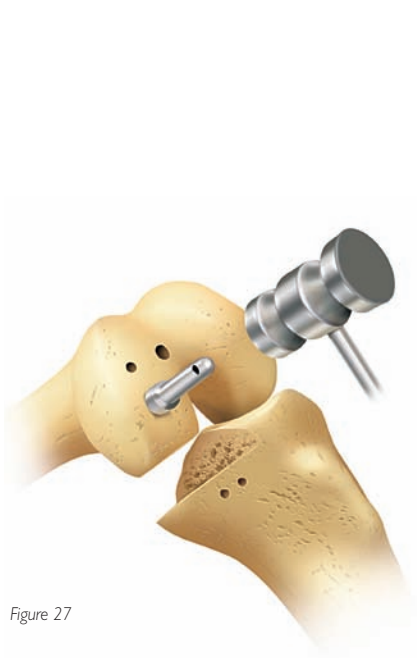


Figure 27

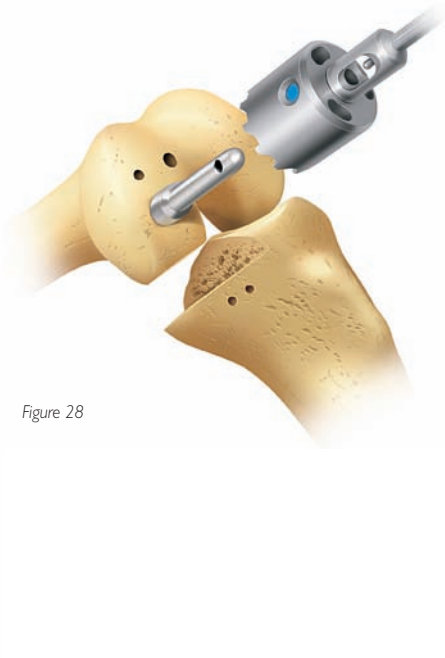


Figure 28

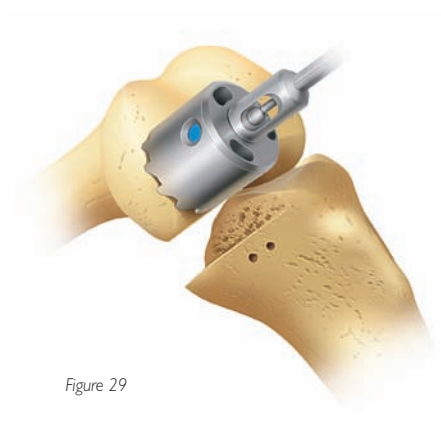


Figure 29

STEP 5: FIRST MILLING OF THE CONDYLE

Insert the 0 spigot (#21), which has the thickest flange, into the large drill hole and tap it until its flange abuts against the bone (Figure 27).

By extending the knee a little and retracting the soft tissues, maneuver the *spherical cutter* (#20) onto the spigot (Figure 28) and into the wound so that its teeth touch the bone (Figure 29). Take care to avoid trapping soft tissues.

When milling, push firmly in the direction of the spigot axis, taking care not to tilt the tool. Mill until the cutter will no longer advance.

If in doubt, continue to mill; there is no risk of over-milling.

THE OXFORD® PARTIAL KNEE SURGICAL TECHNIQUE

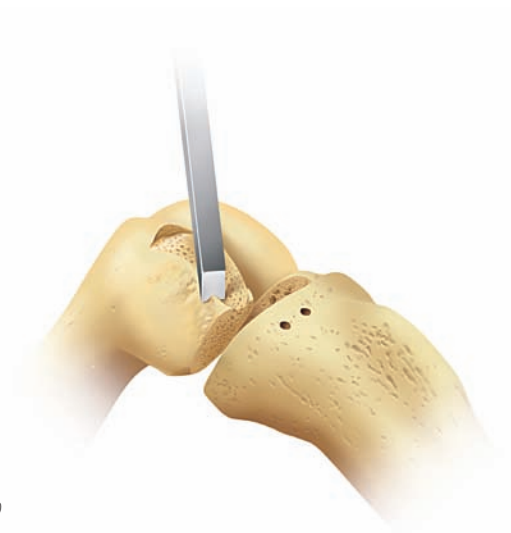

Figure 30

STEP 5: FIRST MILLING OF THE CONDYLE (CONTINUED)

Remove the mill and the spigot and trim off the bone protruding from the posterior corners of the condyle that lie outside the periphery of the cutting teeth (Figure 30).

STEP 6: EQUALIZING THE FLEXION AND EXTENSION GAPS

With the leg in 90 degrees of flexion, insert the tibial template and apply the *femoral trial component* (#14) to the milled condyle, tapping it home with the *femoral impactor* (#9).

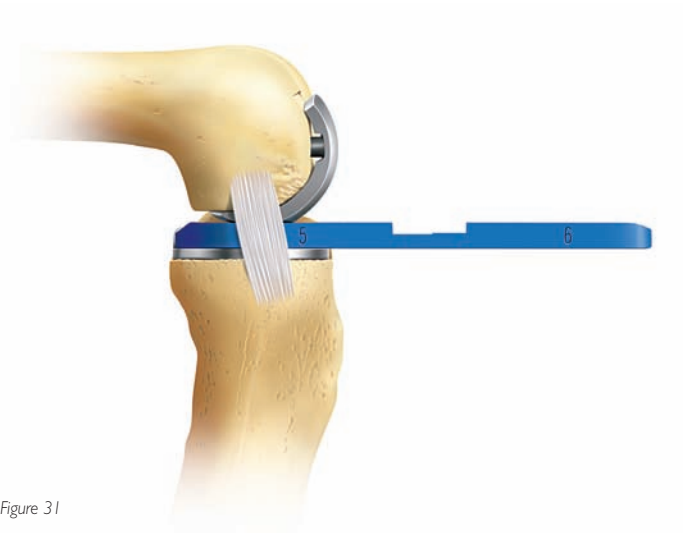


Figure 31

a) Carefully measure the flexion gap with the feeler gauges (Figure 31). (Step 2 has already ensured that the gap is wide enough to accept at least the 4mm gauge.) The gauge thickness is correct when natural tension in the ligaments is achieved. Under these circumstances, the feeler gauge will slide in and out easily but will not tilt.

b) Remove the gauge. It is important to remove the gauge before extending the knee because the extension gap is always narrower than the flexion gap at this stage. If it is left in place, the gauge may stretch or rupture the ligaments as the knee extends.

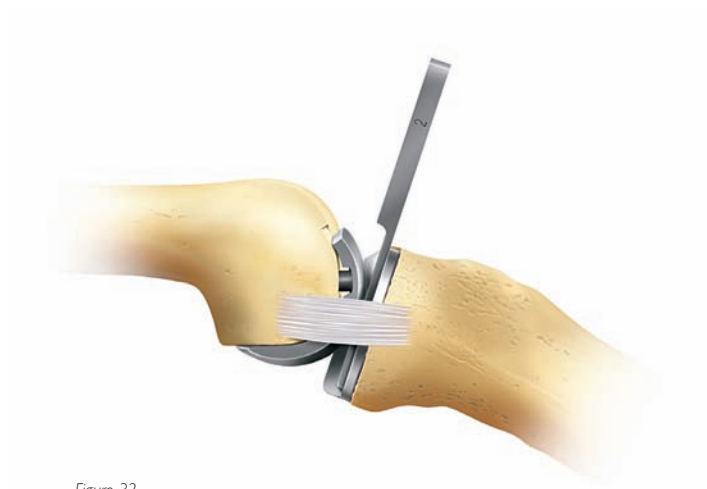

Figure 32

c) Measure the extension gap (Figure 32) in 20 degrees of flexion, not full extension. In full extension, the posterior capsule is tight, and its influence gives a false under-measurement. The extension gap is usually less than 4mm, so the metal feeler gauges (1, 2, and 3mm thick) are used to measure it. If the thinnest of these cannot be inserted, the gap is 0mm.

After each milling, it is necessary to remove the remaining bone on the posterior corners of the condyle (see Figure 30). Also, if the circular disc of bone left under the flange of the spigot is more than 1mm thick, it should be removed. The reference for the spigot will not be lost, as its tip continues to reference off the bottom of the drill hole.

For instance, if the flexion gap measured 5mm and the extension gap 2mm, then the amount of bone to be milled is 3mm. To achieve this, insert a number 3 spigot and mill until the cutter will no longer advance.

The formula for balancing the flexion and extension gaps is as follows:

$$\begin{aligned} \text{Flexion Gap (mm)} - \text{Extension Gap (mm)} &= \text{Thickness of bone to be milled from femur (mm)} \\ &= \text{Spigot number to be used} \end{aligned}$$

THE OXFORD® PARTIAL KNEE SURGICAL TECHNIQUE

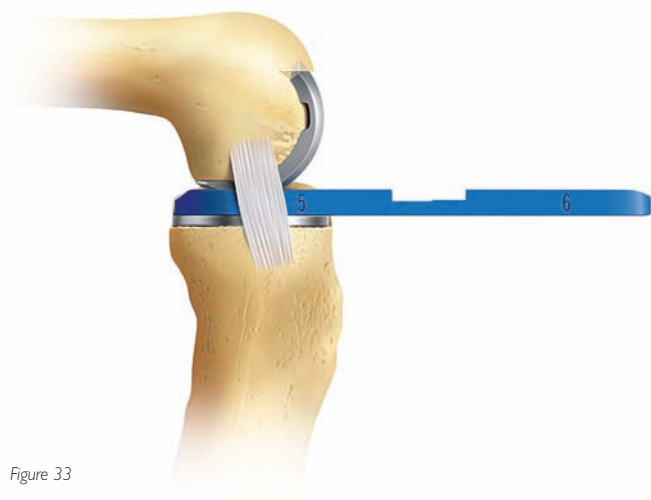


Figure 33

STEP 7: CONFIRMING EQUALITY OF THE FLEXION AND EXTENSION GAPS

With the tibial template and the femoral trial component in place, re-measure the flexion and extension gaps as in step 6. They will usually be found to be the same (Figures 33 & 34).

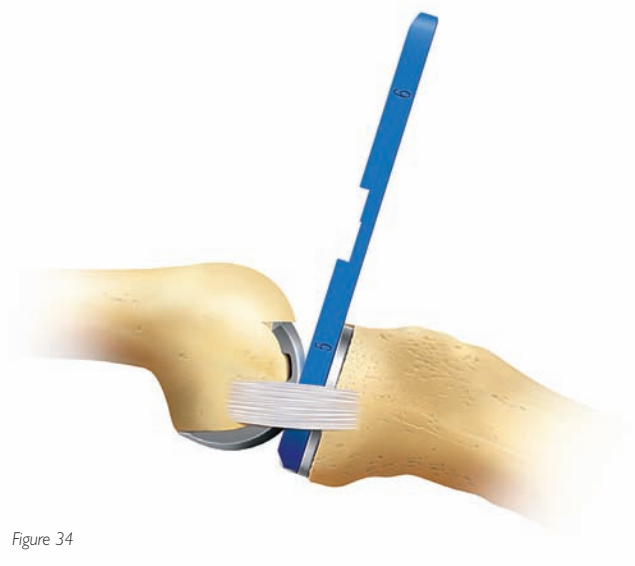


Figure 34

If the extension gap at 20 degrees of flexion is still smaller than the flexion gap, remove more bone with the mill. This can be done, 1mm at a time, by using the sequence of spigots. In the example above, an additional 1mm of bone could be removed by using a number 4 spigot.

Usually the knee is balanced with a number 3 or 4 spigot.

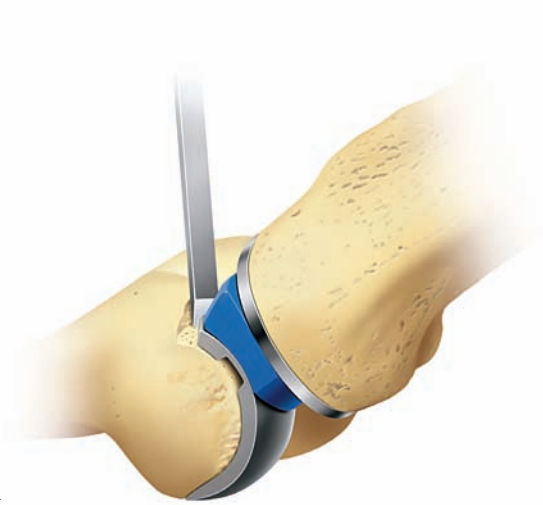

Figure 35

STEP 8: PREVENTING IMPINGEMENT

Trim the anterior and posterior condyle of the femur to reduce the risk of impingement of bone against the bearing in full extension and full flexion.

Apply the *femoral posterior trimming guide* (#32) to the condyle and use the *osteophyte chisel* (#31) to remove any posterior osteophytes (Figure 36).

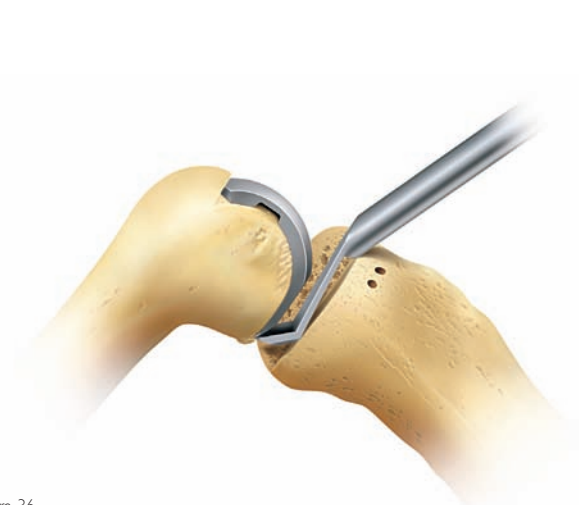

Figure 36

Note: Use a chisel anteriorly to remove bone until there is at least 4mm clearance for the front of the bearing in full extension (Figure 35).

THE OXFORD® PARTIAL KNEE SURGICAL TECHNIQUE

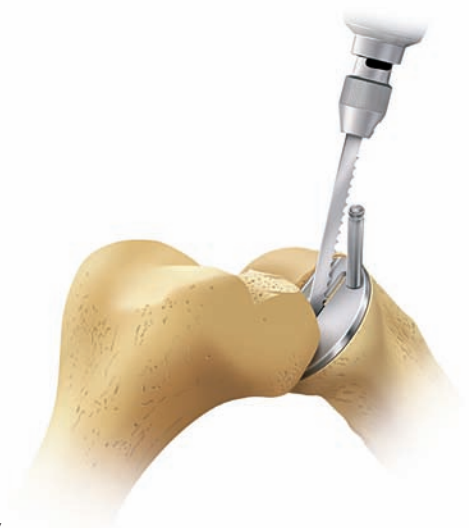

Figure 37

STEP 9: FINAL PREPARATION OF THE TIBIAL PLATEAU

Insert the chosen size of tibial template and position it with its posterior margin flush with the posterior tibial cortex. This is facilitated by passing a small hook over the posterior margin of the tibia.

Fix the template with the transfixing *tibial nail* (#25) (Figure 37). Use a reciprocating saw blade to make 10mm deep cuts along both sides of the slot in the tibial template. Make a third, oblique saw cut in the slot to facilitate removal of bone. Take care that the cuts are no deeper than 10mm.

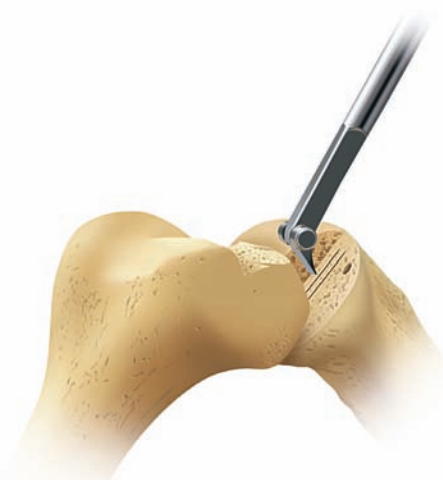

Figure 38

After removing the template, excavate the groove to the correct depth by scooping out the bone with the blade of the *tibial gouge* (#26), taking care not to damage the anterior and posterior cortices (Figure 38).

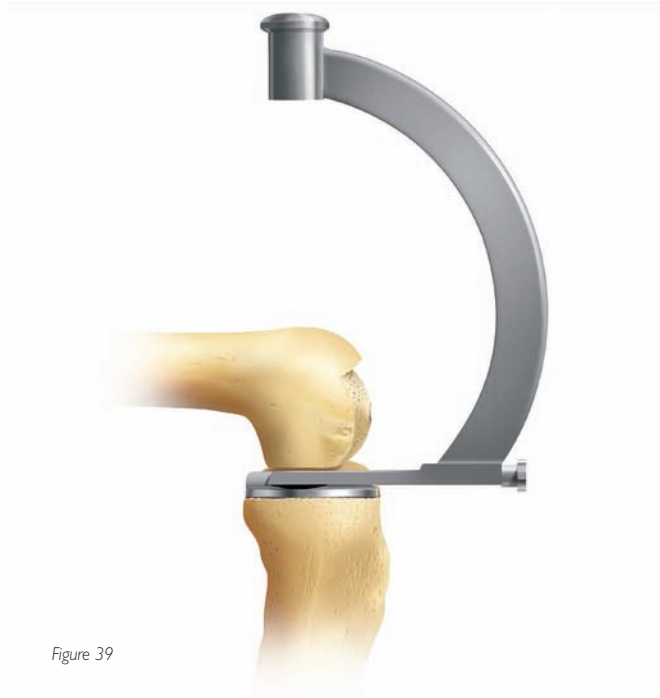

Figure 39

Insert the *tibial trial component* (#23) and tap home with the *tibial impactor* (#22) (Figure 39).

Ensure that it is flush to the bone and that its posterior margin extends to the back of the tibia.

During impaction of the tibial implant, the assistant should support the leg with a hand under the foot to avoid damage to the knee ligaments. Use only a light mallet to avoid the risk of plateau fracture.

THE OXFORD® PARTIAL KNEE SURGICAL TECHNIQUE

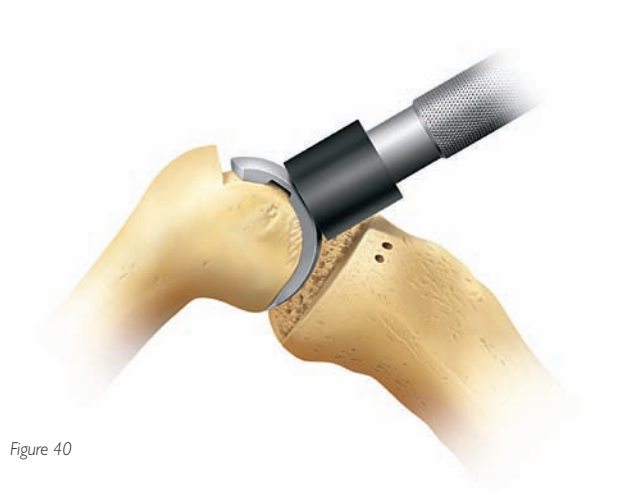

Figure 40

STEP 10: FINAL TRIAL REDUCTION

Insert the tibial and femoral trial components and ensure that they are fully seated by tapping them home with the appropriate impactors (Figures 40 & 41).

Insert a trial meniscal bearing (#17 & 18) of the chosen thickness (Figure 42).

(It is only at this stage that a trial bearing is used. Previously, feeler gauges have been used to measure the gaps because they do not stretch the ligaments. The meniscal bearings have a 3mm high posterior lip which, after multiple insertions, may stretch the ligaments.)

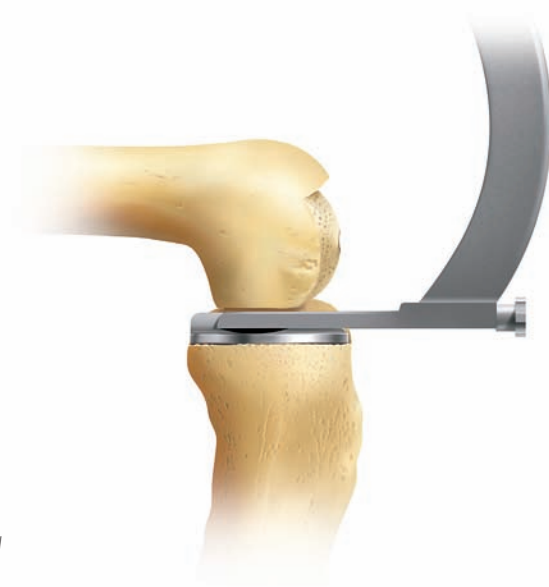

Figure 41

With the bearing in place, manipulate the knee through a full range of motion to demonstrate stability of the joint, security of the bearing and absence of impingement. The thickness of the bearing should be such as to restore the ligaments to their natural tension so that, when a valgus force is applied to the knee, the artificial joint surfaces distract a millimeter or two. This test should be done with the knee in 20 degrees of flexion. In full extension, the bearing will be firmly gripped because of the tight posterior capsule.

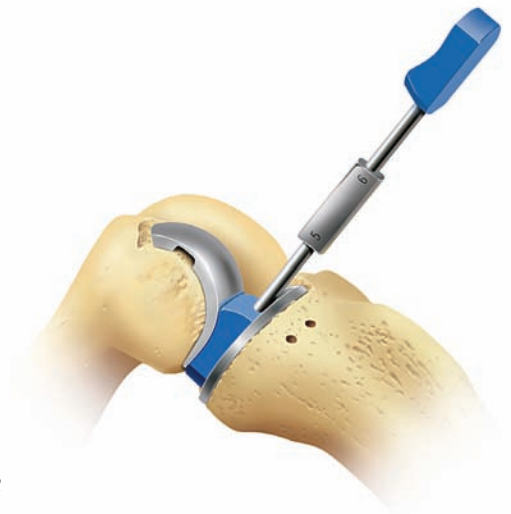

Figure 42

STEP II: CEMENTING THE COMPONENTS

Roughen the femoral and tibial surfaces by making multiple small drill holes made with the *cement key drill* (#29) (Figure 43).

The components are fixed with two separate mixes of cement.

The Tibial Component

Place a small amount of cement on the tibial bone surface and flatten to produce a thin layer. Insert the component and press down, first posteriorly and then anteriorly, to squeeze out excess cement at the front.

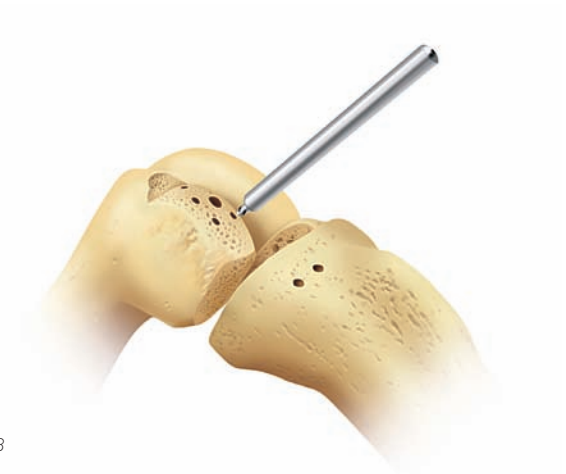

Figure 43

Use the right-angled *tibial impactor* (#22) with a small mallet to complete the insertion. Remove excess cement with a small curette from the margins of the component. Insert the femoral trial component and pressurize the cement while it sets by inserting the appropriate feeler gauge. Hold the leg in 45 degrees flexion while the cement sets. Do not fully extend the leg, as pressure in this position may tilt the tibial component anteriorly.

THE OXFORD® PARTIAL KNEE SURGICAL TECHNIQUE

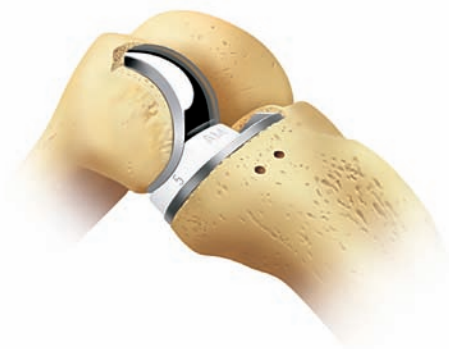

Figure 44

STEP II (CONTINUED)

When the cement has set, remove the feeler gauge and femoral component and look carefully for cement that may have extruded. Slide the flat plastic probe along the tibial articular surface, feeling for cement at the edges and posteriorly.

The Femoral Component

From the second mix, push a little cement into the large femoral drill hole and fill the concave surface of the femoral component with cement. Apply the loaded component to the condyle and impact with the punch held at 30 degrees to the long axis of the femur. Remove excess cement from the margins with a small curette. Pressurize the cement as it sets by inserting the appropriate feeler gauge and holding the leg in 45 degrees flexion.

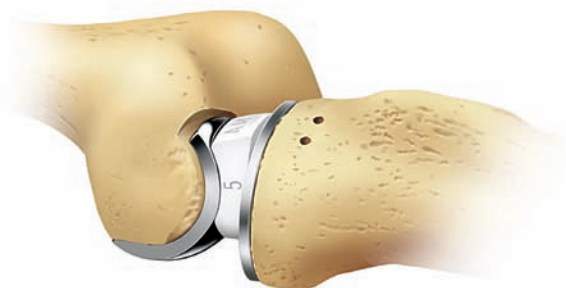













Figure 45

When the cement has set, remove the feeler gauge. Clear the medial and lateral margins of the component of any extruded cement. The posterior margin cannot be seen but can be palpated with a curved dissector.














Complete the reconstruction by snapping the chosen bearing into place (Figures 44 & 45).

Close the wound in a routine manner.













INSTRUMENT KEY

	Instrument	Description
1a		Tibial saw guide assembly – upper shaft, right
1b		Tibial saw guide assembly – upper shaft, left
1c		Tibial saw guide assembly – lower shaft
1d		Tibial saw guide assembly – ankle yoke
1e		Tibial saw guide assembly – ankle strap
2		Headless nail
3		Headed nail
4		Nail puller
5		I/M rod (200mm long)
6		I/M rod (300mm long)
7		Rod pusher
8		Universal removal hook

INSTRUMENT KEY (CONTINUED)

	Instrument	Description
9		Femoral impactor
10		Drill (4mm diameter)
11		Drill (6mm diameter)
12		Slotted femoral saw guide
13		Femoral saw guide
14		Trial femoral component
15		Femoral drill guide
16		Metal feeler gauge (1, 2 and 3mm thick)
17		Trial bearing (3mm thick)
18		Trial bearings (4–9mm thick)
19		Feeler gauges (2–9mm thick)
20		Spherical mill
21		Spigots (numbers 0–7)

INSTRUMENT KEY (CONTINUED)

	Instrument	Description
22		Tibial impactor
23		Trial tibial components
24		Tibial templates
25		Tibial template nail
26		Tibial groove gauge
27		Awl (5mm diameter)
28		Plastic probe
29		Cement key drill
30		Slap-hammer extractor
31		Posterior osteophyte chisel
32		Femoral trimming guide
33		Slotted femoral trimming guide

APPENDIX

POSTOPERATIVE TREATMENT

Walking with a light knee splint and crutches is encouraged on the first postoperative day and patients are allowed to regain knee flexion at their own speed. Forcing flexion of the knee during the first postoperative week often causes pain and is unnecessary since movements are almost always recovered spontaneously.

POSTOPERATIVE RADIOGRAPHIC ASSESSMENT

Postoperative radiographs can be used to measure the technical success of the operation. For this purpose, as well as to facilitate their comparison with follow-up radiographs, the films should be taken in a reproducible manner. Even small variations in the angle of incidence of the X-ray beam can distort the images of the components and make accurate assessment of their positions and bone/cement interfaces difficult.¹¹

RADIOGRAPHIC TECHNIQUE

Anterior Projection

The shape of the tibial component allows it to be used to center the X-ray beam and to align it in all three planes. Position the patient supine on a standard fluoroscopic screening table with an undercouch tube and an image intensifier. Before taking the film, adjust the position of the limb by flexing/extending the knee and internally/externally rotating the leg until the tibial component appears on the screen directly 'end-on.'

Lateral Projection

With the leg flexed 40 degrees, internally/externally rotate the thigh is until the tibial component appears on the screen directly 'edge-on.'

Figure 46

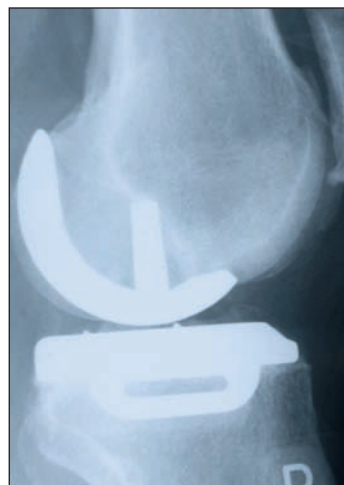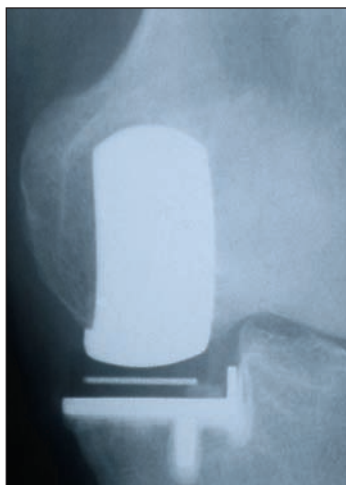


Figure 46 shows the components ideally implanted.

APPENDIX

FOLLOW-UP RADIOGRAPHS

All subsequent radiographs should be taken in the same manner as the immediate postoperative films to allow comparison. Fluoroscopically centered films are particularly appropriate for demonstrating the state of the interface beneath the tibial plateau.

This interface changes gradually during the first year after implantation, after which it should remain unaltered. The typical appearance at one year and ten years is a thin radiolucent line (ca 1 mm). Histologically, the radiolucent line represents a layer of fibrocartilage, with its collagen organized parallel with the plateau. The radiodense line represents a new 'subchondral bone plate.' The trabeculae, which were cut at the operation, attach to this plate and support it. The collagen fibers of the cartilage layer insert into its upper surface.¹⁰

The appearances under the femoral component are the same but are not so easily demonstrated because of the non-planar form of the femoral interface.

The radiographic changes which occur during the first postoperative year result from healing of the cut bone and its remodeling to sustain the new pattern of compressive load applied to it by the rigid implant.

Mature interfaces of this type have proven stable for as long as 15 years in 95 percent of cases (Phase II).¹¹ Therefore it is important not to ascribe clinical symptoms to these 'normal' appearances or to interpret them as evidence of implant loosening.

Oxford™ Meniscal Unicompartmental Knee

Attention Operating Surgeon

DESCRIPTION

The Oxford™ Meniscal Unicompartmental Knee is a medial unicompartmental knee replacement system consisting of a femoral component, a tibial component and a freely mobile meniscal bearing.

Materials:

Femoral Components: CoCrMo Alloy
Tibial Component: CoCrMo Alloy
Meniscal Bearing: Ultra-High Molecular Weight Polyethylene (UHMWPE)

INDICATIONS

The Oxford™ Meniscal Unicompartmental Knee is intended for use in individuals with osteoarthritis or avascular necrosis limited to the medial compartment of the knee and is intended to be implanted with bone cement.

CONTRAINDICATIONS

Contraindications include:

- 1) Infection, sepsis, and osteomyelitis
- 2) Use in the lateral compartment of the knee
- 3) Rheumatoid arthritis or other forms of inflammatory joint disease
- 4) Revision of a failed prosthesis, failed upper tibial osteotomy or post-traumatic arthritis after tibial plateau fracture
- 5) Insufficiency of the collateral, anterior or posterior cruciate ligaments which would preclude stability of the device
- 6) Disease or damage to the lateral compartment of the knee
- 7) Uncooperative patient or patient with neurologic disorders who are incapable of following directions
- 8) Osteoporosis
- 9) Metabolic disorders which may impair bone formation
- 10) Osteomalacia
- 11) Distant foci of infections which may spread to the implant site
- 12) Rapid joint destruction, marked bone loss or bone resorption apparent on roentgenogram
- 13) Vascular insufficiency, muscular atrophy, neuromuscular disease
- 14) Incomplete or deficient soft tissue surrounding the knee
- 15) Charcot's disease
- 16) A fixed varus deformity (not passively correctable) of greater than 15 degrees
- 17) A flexion deformity greater than 15 degrees

WARNINGS

- 1) Improper selection, placement, positioning, alignment and fixation of the implant components may result in unusual stress conditions which may lead to subsequent reduction in the service life of the prosthetic components.
- 2) Improper preoperative or intraoperative implant handling or damage (scratches, dents, etc.) can lead to crevice corrosion, fretting, fatigue fracture and/or excessive wear.
- 3) Do not modify implants.
- 4) Do not reuse implants. While an implant may appear undamaged, previous stress may have created imperfections that would reduce the service life of the implant. Do not treat patients with implants that have been, even momentarily, placed in a different patient.
- 5) Malalignment or soft tissue imbalance can place inordinate forces on the components which may cause excessive wear to the patellar or tibial bearing articulating surfaces. Revision surgery may be required to prevent component failure.
- 6) Care is to be taken to assure complete support of all parts of the device embedded in bone cement to prevent stress concentrations, which may lead to failure of the procedure. Complete preclosure cleaning and removal of bone cement debris, metallic debris, and other surgical debris at the implant site is critical to minimize wear of the implant articular surfaces. Implant fracture and loosening due to cement failure has been reported.
- 7) The surgeon is to be thoroughly familiar with the implants and instruments, prior to performing surgery.

PRECAUTIONS

- 1) As with other surgical procedures, errors of technique are most likely when the method is being learned. To reduce these to a minimum, surgeons are required in the United States and strongly recommended throughout the world, to attend an Instructional Course on the Oxford™ Meniscal Unicompartmental Knee before attempting the operation.
- 2) Biomet joint replacement prostheses provide the surgeon with a means of reducing pain and restoring function for many patients. While these devices are generally successful in attaining these goals they cannot be expected to withstand the activity levels and loads of normal healthy bone and joint tissue.

- 3) Accepted practices in postoperative care are important. Failure of the patient to follow postoperative care instructions involving rehabilitation can compromise the success of the procedure. The patient is to be advised of the limitations of the reconstruction and the need for protection of the implants from full load bearing until adequate fixation and healing have occurred. Excessive activity, trauma and weight gain may contribute to premature failure of the implant by loosening, fracture, and/or wear. Loosening of the implants can result in increased production of wear particles, as well as accelerate damage to bone making successful revision surgery more difficult. The patient is to be made aware and warned of general surgical risks, possible adverse effects as listed, and to follow the instructions of the treating physician including follow-up visits.
- 4) Specialized instruments are designed for Biomet joint replacement systems to aid in the accurate implantation of the prosthetic components. The use of instruments or implant components from other systems can result in inaccurate fit, sizing, excessive wear and device failure.
- 5) Intraoperative fracture or breaking of instruments has been reported. Surgical instruments are subject to wear with normal usage. Instruments, which have experienced extensive use or excessive force, are susceptible to fracture. Surgical instruments should only be used for their intended purpose. Biomet recommends that all instruments be regularly inspected for wear and disfigurement.

POSSIBLE ADVERSE EFFECTS

A time-course distribution of the adverse events reported in the clinical investigation of the Oxford™ Meniscal Unicompartmental Knee using a standard open surgical technique is provided in Table 1.

Table 1 – Time-Course Distribution of Adverse Events reported in the clinical trial for the Oxford™ Meniscal Bearing Unicompartmental Knee* using a standard open surgical technique.

Adverse Events	Frequency							Percent of Population (n=125)
	IO	6 mo	1 yr	2 yr	3 yr	4 yr	≥5 yr	
Local-Operative Site								
Effusion			1					0.8%
Deep Infection				1				0.8%
Degeneration of contralateral condyle						1	3	3.2%
Loose body and/or osteophyte removal		1		2			1	3.2%
Soft tissue damage	2							1.6%
<i>Dislocation</i>				2				1.6%
<i>Component mal-alignment</i>		1						0.8%
<i>Patella dislocation</i>				1				0.8%
<i>Component loosening</i>					1	2	3	4.8%
Post-operative bone fracture		1						0.8%
Trauma		1						0.8%
Mechanical symptoms			1					0.8%
<i>Instability</i>							1	0.8%
<i>Persistent pain</i>					1			0.8%
Wear of bearing due to osteophyte					1			0.8%
Systemic								
Development of rheumatoid arthritis			1					0.8%

* Phase 2 device design

IO = intraoperatively

†All percentages for adverse events are based the number of occurrences reported in a patient population of 125 knee cases.

Those events listed in *italics* are considered device related events.

Boldface numbers represent revisions due to the given adverse event. One additional case was revised at 130 months post-operatively, cause unknown.

The following complications have also been reported in the clinical literature for unicompartmental and total knee arthroplasty designs and could potentially occur with the Oxford™ Meniscal Unicompartmental Knee device.

- 1) Major surgical risks associated with anesthetic including, brain damage, pneumonia, blood clots, heart attack, and death.
- 2) Cardiovascular disorders including venous thrombosis, pulmonary embolism, and myocardial infarction.
- 3) A sudden drop in blood pressure intraoperatively due to the use of bone cement.
- 4) Damage to blood vessels, hematoma, delayed wound healing and/or infection.
- 5) Temporary or permanent nerve damage may result in pain and numbness.
- 6) Material sensitivity reactions.
- 7) Particulate wear debris and discoloration from metallic and polyethylene components of joint implants may be present in adjacent tissue or fluid. It has been reported that wear debris may initiate a cellular response resulting in osteolysis or osteolysis may be a result of loosening of the implant.
- 8) Early or late postoperative, infection, and allergic reaction.
- 9) Intraoperative bone perforation or fracture may occur, particularly in the presence of poor bone stock caused by osteoporosis, bone defects from previous surgery, bone resorption, or while inserting the device.
- 10) Loosening or migration of the implants can occur due to loss of fixation, trauma, malalignment, bone resorption, excessive activity.
- 11) Periarticular calcification or ossification, with or without impediment of joint mobility.
- 12) Inadequate range of motion due to improper selection or positioning of components.
- 13) Dislocation and subluxation due to inadequate fixation and improper positioning. Muscle and fibrous tissue laxity can also contribute to these conditions.
- 14) Fatigue fracture of components can occur as a result of loss of fixation, strenuous activity, malalignment, trauma, non-union, or excessive weight.
- 15) Fretting and crevice corrosion can occur at interfaces between components.
- 16) Wear and/or deformation of articulating surfaces.
- 17) Valgus-varus deformity.
- 18) Transient peroneal palsy secondary to surgical manipulation and increased joint movement has been reported following knee arthroplasty in patients with severe flexion and valgus deformity.
- 19) Patellar tendon rupture and ligamentous laxity.
- 20) Persistent pain.

PATIENT SELECTION

Positive selection factors to be considered include:

- 1) ACL and PCL functionally intact
- 2) Cartilage and bone erosions limited to the anterior and middle parts of the medial compartment. The posterior part of the medial compartment and the lateral compartment having cartilage of normal thickness
- 3) Medial collateral ligament not structurally shortened (i.e. varus deformity correctable)
- 4) Patellofemoral joint damage limited to (or greater on) the medial facets
- 5) Fixed flexion deformity of less than 15 degrees
- 6) Flexion possible to 110 degrees under anaesthetic
- 7) Need to obtain pain relief and improve function
- 8) Ability and willingness of the patient to follow instructions, including control of weight and activity level
- 9) A good nutritional state of the patient, and
- 10) The patient must have reached full skeletal maturity.

CLINICAL STUDIES

A prospective multi-site clinical investigation of the Oxford™ Meniscal Unicompartmental Knee involving 125 knee devices in 107 patients (see Tables 2 and 3) was conducted in the United States to determine the safety and effectiveness of the device when implanted using a standard open surgical technique. All clinical results and adverse events for this investigation were derived from the Oxford™ Meniscal Unicompartmental Knee Phase 2 device, a previous version of the current Phase 3 device, that had a single femoral component size, a universal (left and right) design tibial component of few sizes, and a universal design meniscal bearing component with extended sizes.

Table 2 – Patient Demographics for the Oxford™ Clinical Study (Phase 2 Device)

	All Oxford Knees Enrolled
Total # Knees (# Patients)	125 (107)
Mean Age in years (range)	63±10.6 (29-85)
Sex	Males – 60 Females – 65
Indications	Osteoarthritis – 114 Post-Traumatic Arthritis – 10 Avascular Necrosis – 1
Side	Left – 56 Right – 69
Compartment	Medial – 119 Lateral – 6
Mean Height in Inches (range)	67.0±3.9 (59-77)
Mean Weight in Pounds (range)	187±38.6 (105-256)

Table 3 – Device Accounting for the Oxford™ Clinical Study (Phase 2 Device) based on number of completed clinical follow-up examinations.

	6 months	1 year	2 year	3 year	4 year	5 year
¹ Theoretically Due	125	125	125	113	102	84
² Deaths	0	0	1	2	2	2
³ Revisions	3	4	8	11	13	15
⁴ Expected	122	121	116	100	87	67
⁵ Clinical Follow-Up	100	110	80	83	69	51
⁶ Percent Follow-up	82.0%	90.9%	69.0%	83.0%	79.3%	76.1%

¹Based on the cut-off date when the last patient enrolled reached their 2 year post-operative anniversary

²Cumulative over time

³Any component removed, cumulative over time

⁴Theoretically Due – (Deaths + Revised)

⁵Cases with complete clinical data (i.e., HSS, radiographic), obtained at the specified time point

⁶Clinical Follow-Up / Expected

Each patient was evaluated pre-operatively, and at the immediate and 6, 12, and 24 month post-operative intervals, and annually thereafter until the last patient enrolled had achieved their 24 month follow-up. All operative and post-operative complications, device related or not, were recorded for patients enrolled into the investigation (see Table 1).

Clinical results were evaluated using the Hospital for Special Surgery (HSS) knee scoring system and radiographic data. At each follow-up visit an HSS knee score and anterior/posterior and lateral radiographs were obtained. Radiographs were reviewed by the implanting surgeon. See Table 4 for clinical study results.

A patient was defined as a success if they met all of the following criteria:

- 1) A Good/Excellent HSS score, i.e., > 70 points,
- 2) No radiolucent lines > 1 mm in width surrounding > 50% of the component after 1 year in-situ,
- 3) No progressive radiolucencies, and
- 4) No revision/removal of any components.

Table 4 – Oxford™ Clinical Study Results* (Phase 2 Device) using a standard open surgical technique.

	Preop	1 year	2 years	3 year	4 year	5 year
Cases with complete HSS	123	110	80	83	69	51
Average HSS Score	59.5	89.3	90.0	90.6	90.7	90.4
¹ Cases Rated as Good/Excellent HSS	20/123 (16.3%)	105/110 (95.5%)	77/80 (96.3%)	82/83 (98.8%)	64/69 (92.8%)	50/51 (98.0%)
Femoral Lucencies ≥ 1mm		6/108 (5.5%)	2/80 (2.4%)	2/83 (2.4%)	2/68 (2.9%)	2/51 (2.9%)
Tibial Lucencies ≥ 1mm		5/108 (4.6%)	6/80 (7.5%)	8/83 (9.6%)	7/68 (10.3%)	3/51 (5.9%)
Number of G/E cases with radiolucent lines > 1mm around >50% of component		0	0	0	0	1 (femoral)
Number of G/E cases with progressive radiolucencies		0	0	0	1 (tibial)	0
² Revisions		4	8	11	13	15
³ Cumulative Survivorship		96.75%	93.34%	90.73%	88.83%	86.82%
⁴ Successful Cases		105	77	82	63	49
⁵ Percent Successful		92.5% (105/114)	87.5% (77/88)	87.2% (82/94)	76.8% (63/82)	74.2% (49/66)

*Based on the cut-off date when the last patient enrolled reached their 2 year post-operative anniversary

¹Hospital for Special Surgery score > 70

²Number of components removed at specified time point

³Kaplan-Meier Life Table results

⁴A successful case required a Good/Excellent HSS score, no revision/removal of any component, no radiolucent lines > 1 mm in width surrounding > 50% of the component, and no progressive radiolucencies.

⁵Denominator includes cases with complete HSS and radiographic data, and revisions.

There were a total of 23 revisions reported for the Oxford™ study group (over a follow-up period of at least 9 years), with 8 of these occurring within the first 2 years of implantation. Of the 8 revisions reported at 2 years, 2 were for tibial bearing dislocation, 1 for patellar dislocation, 1 for infection, 1 for component malalignment, 1 for recurrent arthritis due to trauma, 1 for onset rheumatoid arthritis, and 1 for femoral loosening and fracture at the bone-cement interface. In all but 1 case the knees were revised to a total knee prosthesis. For the remaining 15 revisions reported after 2 years, 6 were due to loosening, 4 to progression of osteoarthritis in the lateral compartment, 1 to persistent pain, 1 to instability, 1 to impingement on an osteophyte and subsequent wear of the tibial bearing, 1 to impingement of an osteophyte on the femur, and 1 failed to report a reason. Revisions in this latter group occurred from 2 to 12 years post-operatively.

The survival rate for the Oxford™ Meniscal Unicompartmental Phase 2 device study group at 2 years post-operatively is 93.38%, based on the endpoint of revision/removal of any component. Table 5 displays the Kaplan-Meier life table for survivorship through 8 years post-operatively for the Oxford study group. Survivorship rates for the study group are comparable to those rates seen in the literature for other unicompartmental knee devices and the rates seen in other studies of the Oxford™ Phase 2 device.

Table 5: Survivorship for Oxford™ Clinical Study (Phase 2 Device)

Interval Since Operation (years)	Number in Beginning of Interval	Number of Revisions at End of Interval	% Interval ¹ Survival	% Cumulative ² Survival	95% Confidence Interval
0-1	125	4	96.75%	96.75%	(93.61 - 99.98)
1-2	117	4	96.52%	93.38%	(88.95 - 97.82)
2-3	109	3	97.16%	90.73%	(88.50 - 95.95)
3-4	99	2	97.91%	88.83%	(83.08 - 94.57)
4-5	90	2	97.74%	86.82%	(80.57 - 93.07)
5-6	85	0	100%	86.82%	(80.57 - 93.07)
6-7	65	3	94.92%	82.41%	(75.21 - 89.60)
7-8	50	1	97.87%	80.65%	(73.35 - 87.95)

¹ Percent survival for that interval only, taken at the end of the interval.

² Percent cumulative survival taken at the end of the interval.

In addition, 2 year clinical data from 328 knee cases implanted with the current Phase 3 device, implanted using the minimally invasive surgical technique and minimally invasive surgical instruments specifically developed for the Phase 3 device, was collected from 3 European sites (2 U.K., 1 Holland). European clinical results were evaluated using the Knee Society Score (KSS) scoring system. At 2 years following surgery 5 of the 307 knees (1.6%) with available data had been revised (see Table 6).

Table 6: Results at 2 years for Phase 2 Device using an open surgical technique and Phase 3 Device using a minimally invasive surgical technique.

Clinical Parameters	Oxford Study Phase 2 N=125 knees	Combined European Data* Oxford Phase 3 N=328 knees	European Site 1 Oxford Phase 3 N=208 knees	European Site 2 Oxford Phase 3 N=40 knees	European Site 3 Oxford Phase 3 N=80 knees
Revision Rate ¹	6.8% (8/117)	1.6% (5/307)	2.0% (4/196)	2.7% (1/37)	0% (0/74)
Percent with a Good or Excellent Knee Score ²	N=80 96.3% ³ (77/80)	N=271 83.0% ⁴ (225/271)	N=160 83.1% ⁴ (133/160)	N=37 86.5% ⁴ (32/37)	N=74 81.0% ⁴ (60/74)

*Combined data from European Site 1, Site 2, and Site 3.

European Site 1 = Nuffield Orthopaedic Centre (U.K.), Site 2 = Macclesfield Hospital (U.K.), and Site 3 = Groningen Hospital (Holland).

¹Revision rate (%) at 2 years = cumulative number of revisions / (N – # deaths - # lost to follow up).

²Percent with Good or Excellent HSS or KSS knee score at 2 years.

³Based on HSS knee scoring system.

⁴Based on KSS knee scoring system.

STERILITY

Prosthetic components are sterilized by exposure to a minimum dose of 25 kGy of gamma radiation. Do not resterilize. Do not use any component from an opened or damaged package. Do not use implants after expiration date.

Caution: Federal law (USA) restricts this device to sale by or on the order of a physician.

Manufactured and Distributed by:
Biomet UK Ltd.
Waterton Industrial Estate
Bridgend CF31 3XA, UK

Distributed in the United States by:
Biomet Orthopedics, Inc
P.O. Box 587
Warsaw, Indiana 46581 USA

CE 0086

The information contained in this package insert was current on the date this brochure was printed. However, the package insert may have been revised after that date. To obtain a current package insert, please contact Biomet at the contact information provided herein.

REFERENCES

1. Goodfellow, J.W. et al. The Mechanics of the Knee and Prosthesis Design. *Journal of Bone and Joint Surgery [Br]*. 60-B:358–69, 1978.
2. Argenson, J.N. et al. Polyethylene Wear in Meniscal Knee Replacement. A One to Nine-Year Retrieval Analysis of the Oxford Knee. *Journal of Bone and Joint Surgery [Br]*. 74-B:228–32, 1992.
3. Psychoyios, V. et al. Wear of congruent meniscal bearings in unicompartmental knee arthroplasty—A retrieval study of 16 specimens. *Journal of Bone and Joint Surgery [Br]*. 80-B:976–82, 1998.
4. White, S.H. et al. Anteromedial Osteoarthritis of the Knee. *Journal of Bone and Joint Surgery [Br]*. 73-B:582–86, 1991.
5. Murray, D.W. et al. The Oxford medial unicompartmental arthroplasty, a ten year survival study. *Journal of Bone and Joint Surgery [Br]*. 80-B:983–89, 1998.
6. Price, A. et al. Ten year survival results of Oxford mobile bearing unicompartmental knee arthroplasty in young patients. I.S.T.A. Chicago, 1999.
7. Incavo, et al. Tibial Plateau Coverage in Total Knee Arthroplasty. *Clinical Orthopaedics and Related Research*. 299:81–85, 1994.
8. Keys, G.W. et al. The Radiographic Classification of Medial Gonarthrosis. Correlation with Operative Methods in 200 Knees. *Acta Orthopaedica Scandinavica*. 63 (5):497–501, 1992.
9. Gibson, P. et al. Stress Radiography in Degenerative Arthritis of the Knee. *Journal of Bone and Joint Surgery [Br]*. 68-B:608–9, 1986.
10. Tibrewal, S.B. et al. The Radiolucent Line beneath the Tibial Components of the Oxford Meniscal Knee. *Journal of Bone and Joint Surgery*. 66-B:523–28, 1984.
11. Weale, A.E. et al. Does Arthritis Progress in the Retained Compartments after 'Oxford' Medial Unicompartmental Arthroplasty? *Journal of Bone and Joint Surgery [Br]*. 81-B:783–89, 1999.
12. Bankston, A.B. et al. Comparison of Polyethylene Wear in Machined Versus Moulded Polyethylene. *Clinical Orthopaedics and Related Research*. 317:37–43, 1995.
13. Clarke, I.C. et al. Hip Simulator Wear Testing ArCom® vs Extruded Bar Polyethylene. Presentation. 7th Annual Conference On Techniques & Science for Successful Joint Arthroplasty, October 1995.
14. Gunther, T.V. et al. Lateral Unicompartmental Arthroplasty with the Oxford Meniscal Knee. *The Knee*. 3:33–39, 1996.

Oxford®, AGC®, Vanguard M™ and ArCom® are trademarks of Biomet Manufacturing Corp.

For product information, including indications, contraindications, warnings, precautions and potential adverse effects, see the package insert and Biomet's website.

This material is intended for the sole use and benefit of the Biomet sales force and physicians. It is not to be redistributed, duplicated or disclosed without the express written consent of Biomet.

BIOMET®
ORTHOPEDICS, INC.

P.O. Box 587, Warsaw, IN 46581-0587 • 800.348.9500 ext. 1501
©2007 Biomet Orthopedics, Inc. • www.biomet.com
Form No. BOI-0005.0 REV063007